

Oral Submucous Fibrosis : A Review

¹Minnu Peter Roche, ²Boney Shaji,
³Tony Aby Kurivilla, ⁴Giju George Baby

^{1,2,3} Part I, Annoor Dental College and Hospital,
Muvattupuzha, Kerala

⁴Professor, Dept of Oral Medicine & Radiology
Annoor Dental College and Hospital, Muvattupuzha, Kerala

Abstract

Oral submucous fibrosis (OSMF) is the chronic debilitating and crippling condition affecting any part of the oral cavity. It is well recognised as potentially malignant disorder which is associated mainly with the use of arecanut in various forms. Epithelial atrophy, juxta epithelial inflammation and fibrosis of the lamina propria are common findings. It is characterised by inflammation and progressive fibrosis of the submucosal tissue. The pathogenesis of the disease includes various factors like arecanut chewing, chillies nutritional deficiencies and genetic processes. The management of OSF has been the subject of controversy ever since Schwartz first described the condition in 1952. Through this article, an attempt is made to update the knowledge regarding aetiology and its therapeutic and surgical management which improves the life expectancy of patients suffering from OSF.


Keywords: Aetiology and management, arecanut, oral submucous fibrosis, Clinical Presentation, Pathogenesis.

INTRODUCTION

Oral submucous fibrosis (OSMF) is a chronic insidious disease affecting any part of the oral cavity and sometimes the pharynx. Although, occasionally preceded by or associated with vesical formation, it is always associated with a juxta-epithelial inflammatory reaction followed by fibroelastic changes of lamina propria with epithelial atrophy, leading to stiffness of oral mucosa and causing trismus and inability to eat.¹ OSF was first reported in India in 1953 by Joshi and he coined the term submucous fibrosis of palate and faucial pillars. Various other names suggested were diffuse oral submucous fibrosis (Lal, 1953), idiopathic scleroderma of the mouth (Su, 1954), idiopathic palatal fibrosis (Rao, 1962) and sclerosing stomatitis (Behl, 1962).² OSF is a disease commonly occurring in the South East Asians and Indian population. Indian population has the highest rate of incidence from the past to the present. Reports from the aNorth Western India give an incidence of 2.6 and 8.5 per 100,000 per year for amales and females, respectively; figures in south of India were higher 9 and 20 per 100,000 per year for males and females, respectively.³

Male paredominance was reported by various authors Sinor and Kumar. Wide variation in ages were reported by various authors, Pindborg gave an average range for male 53.6 years and females 37.7 years, Babu and Trivedy reported 23% of patients age ranged between 14 and 19 years. Other authors reported incidence of OSF in younger populations ranging from 20 to 30 years.

AETIOLOGY: The condition is thought to be multifactorial in origin. Various studies suggested that arecanut is the main aetiological factor for OSF and the only risk for OSF among people who probably have a genetic predisposition to the disease. Other aetiological factors suggested are lime, tobacco, chillies, immunological disorders nutritional deficiencies and collagen disorders.



Arecanut

The husked whole fruit of arecanut tree and betel is the inner kernel or seed obtained after removing husk. The active alkaloid found in betel nuts is arecoline, which stimulates fibroblast to increase production of collagen at a higher rate than normal. Also a high amount of copper content is found in arecanut which on chewing it for 5-30 min increases soluble copper levels in oral fluids, which is an initiating factor in OSF.⁴

Immune system

In OSF cases, the transforming growth factor-beta (TGF-B) and interferon-gamma (IFN- γ) levels are low and the results are correlated with use of betel quid. Other diseases like rheumatoid arthritis, systemic lupus erythematosus (SLE) and scleroderma are associated with unique human leukocyte antigen (HLA) - DR antigens and similar association is found for OSF.

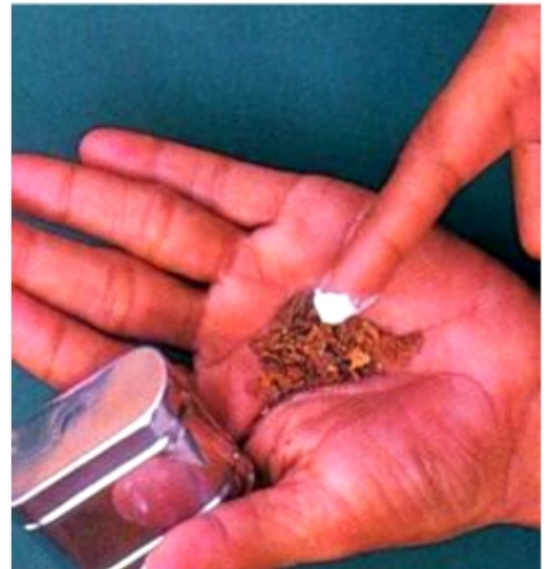Nutritional deficiencies

OSF cases have been suspected with subclinical vitamin B complex deficiency. Iron deficiency anaemia, vitamin B complex deficiency and malnutrition are promoting factor that derange the repair of inflamed oral mucosa leading to scarring and defective healing. Chillies also play an aetiological role in OSF as its active ingredient Capsaicin (vanillylamide of 8-methyl-6-nonenic acid) acts as a predisposing factor for fibrosis (Rajendran, 1994).



Tobacco and Lime

Freezed dried forms of mawa, gutkha and pan masala are commercially available with high concentration of arecanut per chew. They cause more irritation to the oral mucosa than self-prepared betel quid.



Malignant transformation and pre-cancerous nature of oral submucous fibrosis:

Paymaster in 1956 found the pre-cancerous nature of OSMF when he observed squamous cell carcinoma in one-third of the OSF cases. A malignant transformation rate of 4.5% in 66

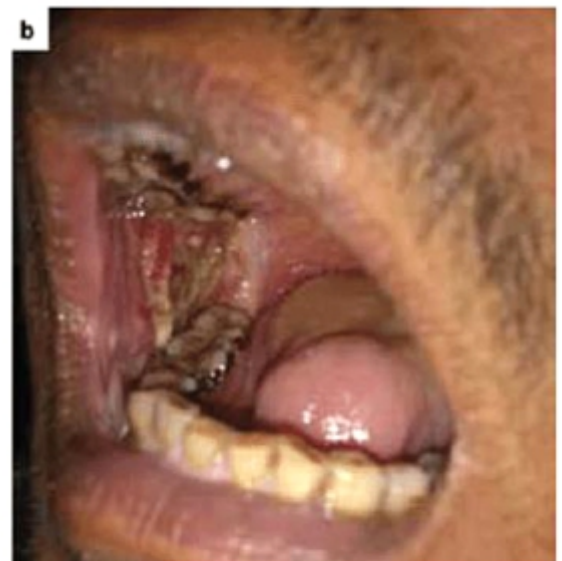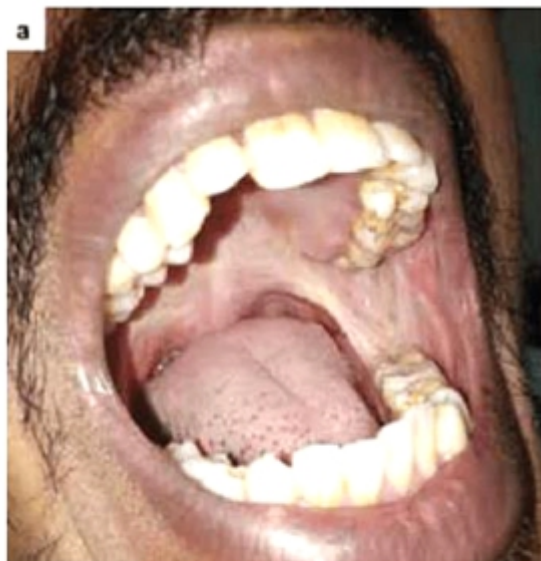cases of OSMF during a period of 4-15 years was observed by Pindborg. The malignant transformation rate in Taiwan was estimated as 3.27-8.63%, whereas in a study by Patil and Maheshwari (2014) reported malignancy in 4.6% OSMF cases.

Classification system

Recent classification systems:

Kerr gave the following grading system for OSMF as:

- ❖ Grade 1: Mild: Any features of the disease triad for OSMF may be reported and inter incisal opening >35mm



Representative clinical images of patients affected by Oral Submucous Fibrosis (OSMF) and OSMF associated with oral squamous cell carcinoma (OSMF-OSCC). (A) OSMF clinically demonstrating a whiteness and fibrosis of the retromolar area and soft palate. (B) OSMF-OSCC with extensive ulcerative areas.

- ❖ Grade 2: Moderate: Above features of OSMF and inter-incisal limitation of opening between 20-35 mm
- ❖ Grade 3: Severe: Above features of OSF and inter-incisal opening <20 mm
- ❖ Grade 4A: Above features of OSMF with other potentially malignant disorders on clinical examination
- ❖ Grade 4B: Above features of OSMF with any grade of oral epithelial dysplasia on biopsy
- ❖ Grade 5: Above features of OSMF with oral squamous cell carcinoma. More et al⁵ gave the following classification based on clinical and functional parameters as:

Clinical staging:

Stage 1(S1): Stomatitis and/or blanching of oral mucosa.

Stage 2 (S2): Presence of palpable fibrous bands in buccal mucosa and oropharynx with or without stomatitis.

Stage 3 (S3): Presence of palpable fibrous bands in buccal mucosa and or oropharynx and in any other part of oral cavity with or without stomatitis.

Stage 4 (S4):

A) Any one above stage along with other potentially malignant disorder.

Example: oral leukoplakia, oral erythroplakia etc.

B) Any one of above stage along with oral carcinoma

Functional staging

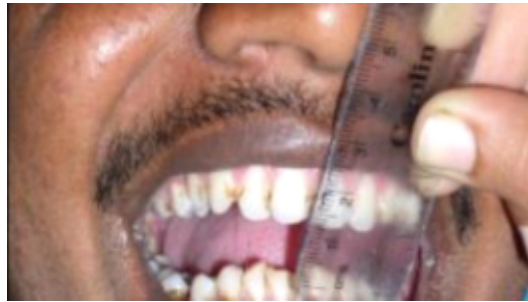M1: interincisal mouth opening upto or greater than 35mm.

M2: interincisal mouth opening between 25-35mm.

M3: interincisal mouth opening between 15-25mm.

M4: interincisal mouth opening less than 15mm.

Prakash et al⁶ assessed the morphologic variants of soft palate by conducting a clinic-



radiological study. The authors based on these variants assessed the severity of OSMF to establish it as a basis for staging of OSMF.

Six morphologic variants were delineated as follows:

Type 1: Leaf shaped

Type 2: Rat tail shaped

Type 3: Butt shaped

Type 4: Straight line

Type 5: Deformed S

Type 6: Crook shaped.

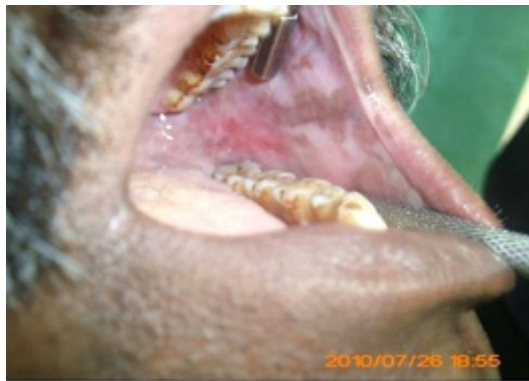Clinical Presentation

OSMF is seen typically between the age of 20 and 40 and is often associated with the habitual use of compounds containing areca (betel), nut and tobacco in various forms are placed in the oral cavity for extended periods of time and often are replaced up to several times per day. Oral submucous fibrosis presents as a whitish yellow change that has a chronic, insidious biological course. It is characteristically seen in the oral cavity, but on occasion it may extend into the pharynx and the esophagus. Submucous fibrosis occasionally may be associated with vesicle formation. Over time, the affected mucosa, especially the soft palate and the buccal mucosa loses its resilience and shows limited vascularity and elasticity. This process then progresses from the lamina propria to the underlying musculature. Fibrous bands are readily palpable in the soft palate and the buccal mucosa. The clinical result is significant trismus with considerable difficulty in eating.

Patient may give history of either all or few of these symptoms that include:

Inability to open the mouth (trismus) due to fibrosis in the dense tissue around the pterygomandibular raphae

- ❖ Pain on palpation in the sites where submucosal fibrotic bands are developing
- ❖ Pain or burning sensation upon consumption of spicy food stuffs.
- ❖ Increased salivation
- ❖ Change of gustatory sensation.
- ❖ Hearing loss may occur due to stenosis of the Eustachian tubes.
- v Dryness of the mouth.
- ❖ Dysphagia to solids (if the esophagus is involved).

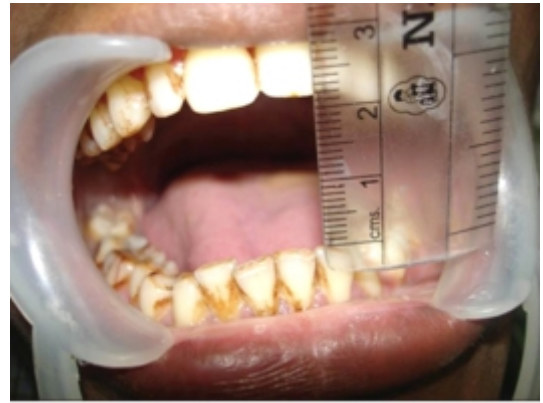

Investigation in OSMF:

1. Complete Hemogram
2. Toluidine blue test
3. Biopsy :- Incisional biopsy
4. Immunofluorescent test :
 - (a) Direct
 - (b) Indirect

MANAGEMENT

OSMF is well known for its resistant and chronic nature. Being a premalignant condition with debilitating consequences, no conservative treatment that has given complete resolution of symptoms is identified till date. Various treatment modalities are available to treat this condition which includes medicinal approach, surgical management and physiotherapy. Proper treatment begins with education of the patient regarding the ill effects of



arecanut and related chewing products. The patient should be informed about the irreversible nature of the disease despite quitting the habit and possibilities of developing oral cancer. Medical management Includes

- Antioxidants
- Micronutrients
- Intralesional injections
- Corticosteroids
- Hyaluronidase
- Placental extracts
- IFN- γ

Surgical treatment

Medical management

OSMF is associated with impaired nutritional status; therefore, various investigators have supplemented the patients with multiple micronutrients which include zinc, vitamin A, B, C, iron, folic acid, copper, calcium and manganese. In a study by Kumar, 82 OSMF patients were treated for 12 weeks. They were divided into five groups. Group A were given 50,000IU of vitamin A, Group B – vitamin A 50,000IU with zinc sulphate 220 mg TDS, Group C - zinc sulphate 220 mg TDS, Group D - zinc sulphate 220 mg TDS with intralesional hydrocortisone 4 mg/week and Group E - intralesional hydrocortisone 4 mg/week. It was observed that oral zinc either alone or in combination with vitamin A or corticosteroids were found beneficial in the treatment of OSMF.⁷

Several glucocorticoids are used for the treat-

ment of OSMF, short acting (hydrocortisone), intermediate acting (triamcinolone) and long acting (betamethasone and dexamethasone). They act by inhibiting inflammatory factor and increasing apoptosis of inflammatory cell, thereby partially relieving symptoms of early stage OSMF. A combination of chymotrypsin (5000 IU), hyaluronidase (1500 IU) and dexamethasone (4 mg) twice weekly submucosal injection for 10 weeks. Current concept is based on the use of intralesionals injected into fibrotic band biweekly for 6 to 8 weeks along with mouth-opening exercises.⁸ Placentrex is basically aqueous extract of human placenta which contains enzymes, vitamins, aminoacids, nucleotides and steroids. Placentrex causes biogenic stimulation and increases vascularity of tissues based on principal of tissue therapy which was introduced by Filatov in 1933. It has been found by various authors that placenta extract significantly improves mouth opening, burning sensation, colour of mucosa and reduction in fibrotic bands.

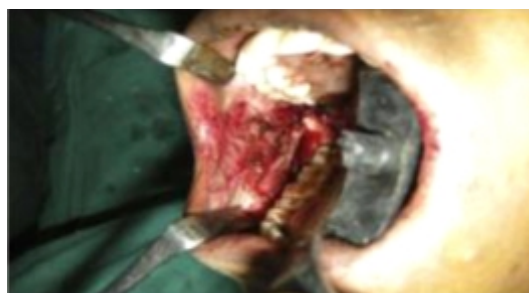IFN- γ is proposed to reduce fibroblast proliferation and collagen synthesis and upregulate collagenase synthesis and antifibrotic cytokines. Previously injection when given intralesionally has showed clinical improvement in the cases of hypertrophic scars and keloids. When intralesional IFN- γ was tried in OSMF patients it showed increased mouth opening, suppleness of the mucosa and reduction in burning sensation

Pentoxifylline is methylxanthine derivative that has vasodilating properties and increases mucosal vascularity. It acts by suppressing leukocyte function, altering fibroblast physiology and stimulating fibronolysis. Pentoxifylline 400 mg three times daily for 7 months was used as an adjunct therapy for OSMF. Levamisole 50 mg TDS for three alternate weeks alone have sure significant improvement in mouth opening and burning sensation. Colchicine inhibits collagen synthesis and increases collagenolytic activity and has found to be of use in OSMF. In a study

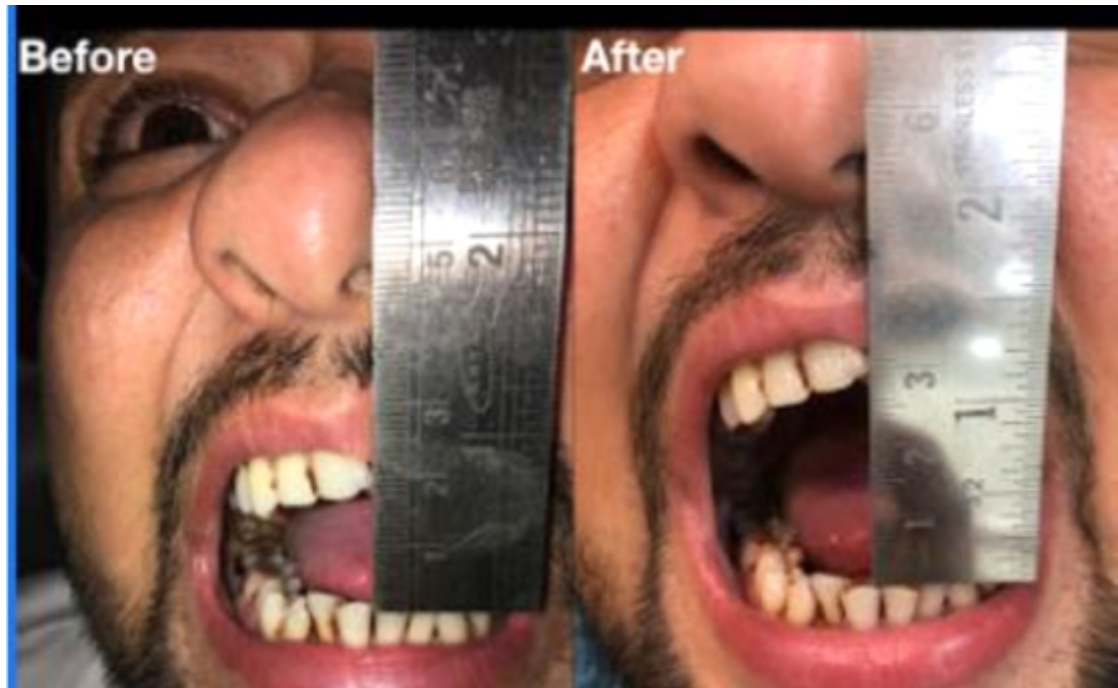by Krishnamoorthy reported that 0.5 mg colchicine orally, twice daily along with intralesional 0.5 ml hyaluronidase 1500 IU gives significant improvement in burning sensation and mouth opening.

Aloe vera acts as a wound-healing hormone and serols in aloe vera have strong anti-inflammatory properties. Sudarshan. reported use of aloe vera topically in mild stage OSMF and has found improvement in burning sensation and mouth opening as compared to antioxidant therapy. Spirulina, a microalgae which contains beta carotene, tocopherols and phenolic acid has antioxidant properties. Shetty. in a study used 500 mg spirulina twice daily as an adjuvant therapy in early management of OSMF. Surgical modalities for the treatment of OSMF are chosen according to the clinical stage of OSMF. Surgical excision of fibrotic tissue and covering the defect with fresh human amnion, buccal pad fat grafts. Bande did the comparison of extended nasolabial flap with the platysma myocutaneous muscle. Flap for reconstruction of intraoral defect after release of OSMF and revealed that both the procedure are equally effective in management, but extraoral scar was not aesthetically acceptable in the nasolabial group.

Oral stent can also be used as an adjunct to pre-



vent surgical relapse. Khanna and Andrade treated advanced cases of OSMF by a new surgical technique of palatal island flap. The latest use of lasers in the surgical management of OSMF is found efficacious. Talsanil used laser with follow-up physiotherapy to reduce trismus in OSMF and concluded that diode



laser is an inexpensive and an alternative method which requires less hospital stay and follow-up compared to other surgical methods.

CONCLUSION

Oral submucous fibrosis (OSMF) is a debilitating but preventable disease and considering the malignant potential of the diseases, early diagnosis and proper management is essential in reducing the mortality of oral cancer. OSMF is mainly a disease of Indian sub-continent where arecanut chewing is rampant. Thus there is an urgent need to initiate public health education measures to educate people about the debilitating, oral premalignant condition before it is too late. Till date, no definitive and widely excepted treatment is currently available. Being a chronic debilitating disease there is a need of herbal medication to be used for longer periods as they have lesser side effects.

REFERENCES

1. Pindborg JJ, Sirsat SM. Oral submucous fibrosis. *Oral Surg* 1966;22:764.
2. Pindborg JJ, Chawla TN, Srivastava AN, Gupta D. Epithelial changes in oral submucous fibrosis. *Acta Odon Scandinav* 1965;23:277-86.
3. Gupta S, Reddy MV, Harinath BC. Role of Oxidative stress and anti-oxidants in aetiopathogenesis and management of oral submucous fibrosis. *Indian J Clin Biochem* 2004;19:138-41.
4. More CB, Das S, Patel H, Adalja C, Kamatchi V, Venkatesh R. Proposed clinical classification for oral submucous fibrosis. *Oral Oncol* 2012;48:200-2.
5. Prakash R, Mohan S, Verma S, Singh U, Agarwal N. Morphometric evaluation of soft palate in oral submucous fibrosis: A digital cephalometric analysis. *West Afr J Radiol* 2014;21:7-11.