Dentigerous Cyst: A Review Article

Sarangi Varma, Rinu Shajan, Riswana Muhamed
Sangeeth Sunil, Samya Nour

Final year Part I BDS Students
Dept of Oral Medicine and Radiology
Annoor Dental College and Hospital, Muvattupuzha

Abstract

Odontogenic cysts which are commonly encountered in dental practice are the radicular cysts and dentigerous cysts. Other than the developmental origin of dentigerous cysts, an inflammatory origin has also been suggested. It has been reported that inflammation progressing from the root apex of the deciduous tooth brings about the development of the dentigerous cyst around the unerupted permanent tooth. Radiographically, pericoronal radiolucency was seen attached to the cementoenamel junction of the impacted tooth and in continuation with the lamina dura of deciduous tooth. Microscopically, the cystic cavity was lined by reduced enamel epithelium like lining, which was hyperplastic to anastomosing in some cases.

INTRODUCTION

The dentigerous (follicular) cyst is recognized as one of the most common lesions of the jaws. It is generally difficult to distinguish between a small dentigerous cyst and a large dental follicle despite the availability of both radiographic and histologic information. At present, identifying a cystic cavity at the time of surgery may be the only reliable way to arrive at a definitive diagnosis when radiographic and histologic features are insufficient to distinguish between a small dentigerous cyst and a large dental follicle.

DISCUSSION

Dentigerous cysts are benign odontogenic cysts. It is associated with crowns of unerupted teeth. The dentigerous cysts are mostly revealed by routine radiographic inspection or by the expansion of affected region The pathogenesis of dentigerous cyst is still a contentious. Three feasible mechanism has been planned for histogenesis of the cyst by Benn and Altini. They proposed that the developmental dentigerous cyst might form a dental follicle and become swollen which is a source of inflammation being a non-vital tooth. The second mechanism they proposed was the formation of a radicular cyst at an apex of a non-vital deciduous tooth followed by the occurrence of its permanent sucessor into the radicular cyst resulting in a dentigerous cyst of extra follicular origin. They also suggested that, the follicle of permanent successor might get secondarily infected from either periapical inflammation of a non-vital predecessor or other source which leads to a dentigerous cyst formation. Earlier reports of dentigerous cysts associated with non-vital predecessors support this mechanism. Available reports in our case indicated that infection of the predecessor (second primary molar) could have be one of the source of inflammation of the dentigerous cyst. Unerupted tooth surrounded by a dentigerous cyst may or may not show enamel hypoplasia. Enamel hypoplasia is seen when a dentigerous cyst commences at an early stage of development of tooth. The cyst originating after the completion of tooth development, enamel hypoplasia is not seen Dentigerous cysts are usually single lesions. Bilatral and multiple cysts has been reported in patients with syndromes, such as basal cell nevus syndrome, mucopolysaccharidosis and cleidocranial dysplasia.

RADIOLOGICAL TYPES

Mostly a well defined, unilocular radiolucency on radiograph.

Usually present with a sclerotic rim.

Can lead toresorption of adjacent teeth.

Three different radiographic relationships between involved tooth and cyst described:

1. Central variety:

Most common radiographic type.

Cyst develops around and surrounds the entire crown of tooth, thus tooth appears to be erupting into the cyst.

2. Lateral variety:

Cyst develops at lateral tooth root and only partially surrounds crown.

3. Circumferential:

Cyst develops around crown and extends down the root(s), Thus roots also appear within the cyst.

More aggressive odontogenic lesions such as odontogenickeratocyst, ameloblastoma, and other odontogenic tumors can have identical radiographic features.

Bilateral dentigerous cysts are uncommon.

Radiographic differential diagnosis for bilateral or multifocal 'cystic' lesions around impacted / partially impacted posterior teeth in a young person may include:

• Odontogenickeratocyst (keratocysticodontogenic tumor)

• Cherubism

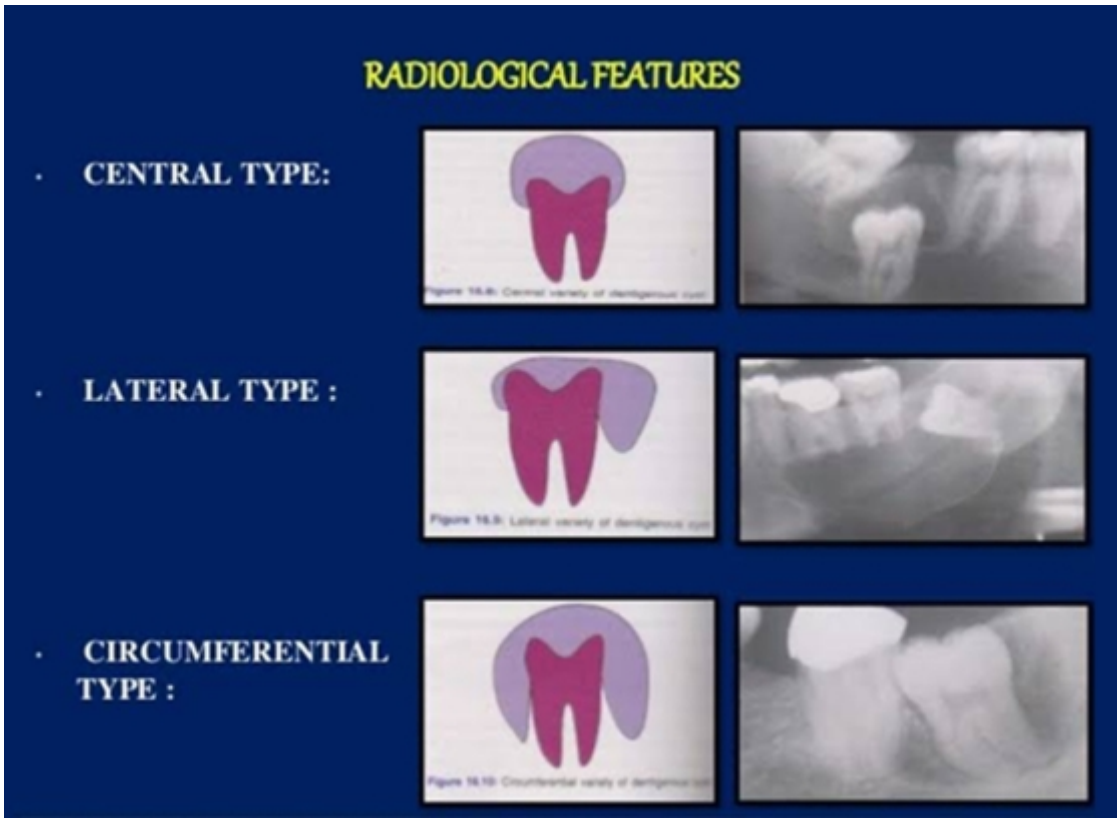

- Bilateral buccal bifurcation cysts
- Enlarged dental follicles
- Multiple hyperplastic calcifying follicles
- Mucolipidosis Type III, or pseudo-Hurler polydystrophy
- Maroteaux-Lamy syndrome, also known as mucopolysaccharidosis type VI
- Amelogenesisimperfect
- Tuberous sclerosis or cleidocranial dysplasia

The radiographic distinction between an enlarged dental follicle and a small dentigerous cyst can be arbitrary.

Generally, a pericoronal radiolucency that is larger than 3 to 4 mm in diameter is considered suggestive of cyst formation.

RADIOLOGICAL FEATURES

Radiographically, dentigerous cysts appear as unilocular well defined pericoronal radiolucencies centred on an impacted or unerupted tooth. They have a skinny regular sclerotic margin and expand the overlying cortex without cortical breach (unless superimposed fracture or infection). Their size is extremely variable, starting from only slightly greater in size than a traditional follicle to very large, appearing to hollow-out the bulk of the jaw.

The roots of teeth are often outside the cyst. There can also be erosion or resorption of the roots of adjacent teeth.

TREATMENT AND PROGNOSIS

Treatment usually involves removal of the entire cyst and the associated unerupted tooth. In patients with a very large lesion or who are unfit medically, marsupialisaiton is an option.

Recurrence is uncommon but may occur if parts of the cyst lining are left in situ.

COMPLICATIONS

- Pathological jaw fracture may result if the cyst is large enough

• In rare cases, dentigerous cysts may transform into mural ameloblastoma

• There is a possibility for development of squamous cell carcinoma in the context of chronic infection

DIFFERENTIAL DIAGNOSIS

When small, it is difficult to distinguish a dentigerous cyst from a large but normal dental follicle.

When large, the differential diagnosis is essential with the purpose of distinguishing from of lytic lesions of the jaw like:

• Radicular cyst (periapical cyst)

• Ameloblastoma

• Odontogenic keratocyst (OKC)

• Aneurysmal bone cyst (ABC)

• Cherubism (Familial fibrous dysplasia)

• Stafne cyst.

REFERENCES

1. Gupta S, Umesh K, Warad NM, Ahmed S. Fibrous dysplasia of maxillary bone: A case report. Al Ameen J Med Sci 2011;4:92-7.
2. Mahadesh J, Gowda C, Devi L, Kokila G. Fibrous dysplasia of the jaw bones: Clinical, radiographical and histopathological features. Report of two cases. J Dent Sci Res, 2011;2:18-25
3. Crawford LB. An unusual case of fibrous dysplasia of the maxillary sinus. Am J OrthodDentofacialOrthop 2003;124:721-
4. Cholakova R, Kanasirska P, Kanasirski N, Chenchev, Dinkova A. Fibrous dysplasia in the maxillomandibular region - Case report. J IMAB 2010;16:10-3.
5. Agarwal MM, Balaji N, Sumathi MK, Sunitha JD, Dawar G, Rallan NS. Fibrous dysplasia: A review. TMU J Dent 2014;1:25-9.