Predictable restoration of endodontically treated teeth - a short review and case report on overlay

Beulah Mary Bejoy[1], Liza George[2], Josey Mathew[3]
Tom Varghese[4], Sinju Paul[4], Dhanya John[4]

[1]Post Graduate Student
Department of Conservative Dentistry and Endodontics
Annoor Dental College and Hospital, Muvattupuzha.

[2]Professor and Head of the Department
Department of Conservative Dentistry and Endodontics
Annoor Dental College and Hospital, Muvattupuzha.

[3]Professor
Department of Conservative Dentistry and Endodontics
Annoor Dental College and Hospital, Muvattupuzha.

[4]Senior Lecturer
Department of Conservative Dentistry and Endodontics
Annoor Dental College and Hospital, Muvattupuzha.

Corresponding author

Beulah Mary Bejoy
Post Graduate Student
Department of Conservative Dentistry and Endodontics,
Annoor Dental College and Hospital, Muvattupuzha.
Email: beulahbejoy@yahoo.co.in

Abstract

The restoration of Endodontically Treated teeth (ETT) is a topic that is extensively studied and yet remains controversial from many perspectives. Many factors such as the instrumentation techniques used for canal preparation, irrigation protocol or the obturation methods have long-term functional effects on endodontically treated teeth. Usually ETT have inadequate remaining coronal structure as a result of caries, trauma orcavity preparation and present higher risk for biomechanical failure when compared to vital teeth, making the management and decision of the restoration a challenging procedure in the field of restorative dentistry. The type of restorative materials used and an appropriate restoration that conserves the remaining tooth structure are the factors that affect the longevity of endodontic treatment. The quality and integrity of the remaining tooth structure should be preserved in all cases to provide a solid and reliable base required for the restoration and structural strength of the restored tooth.

A successful clinical outcome of endodontically treated teeth depends on adequate root canal treatment as well as on the proper restorative treatment done afterwards. Varieties of treatment option are involved in the restoration of endodontically treated teeth and represent a challenging task for clinicians. (Table 1)

Restoration of root filled teeth can be challenging due to the difference in the structural integrity between vital and non-vital root filled teeth. Irreversible chemical-physical (dehydration of dentin; reduction of microhardness; collagen alteration; effects of irrigants and medicaments) and especially bio-mechanical changes (loss of tooth structure; loss of proprioception), due to the endodontic treatment, increase the propension to dental fracture and condition the restoration options for the clinician.[1] The objectives of a restoration following root canal treatment and re-treatment are: to restore form, function and aesthetics, to prevent bacterial micro-leakage into the root canal system,[2] to ensure periodontal health, to protect the residual tooth structure against fracture, to prevent fracture and wear of the restoration and the abrasion of the antagonistic teeth.[3] The final restoration should commence as soon as possible after root canal treatment, better in the same visit of the endodontic treatment, in order to prevent coronal micro-leakage.[4] The type of restoration chosen for a root filled tooth depends on the amount of remaining hard tooth structure available and may influence long-term survival and cost. The aim of this paper is to analyze the therapeutic options for the post-endodontic restorations, describing the clinical advantages of the conservative adhesive techniques and the basic principles fundamental for long-term success.

Various improvementsin adhesive techniques, composite resin materials, fiber posts, and indirect ceramic materials has led to the recent changes in the methods available for restoring endodontically treated teeth.

Advantages of the conservative bonded techniques[1]

- Bioeconomy of Dental Tissues
- Bioeconomy of Periodontal Tissues
- Reinforcing of Healthy Residual Dental Tissues
- Aesthetic, Ergonomic and Economic Advantages

(1) Bioeconomy of dental tissues

Direct relationship exists between remaining tooth structure and fracture resistance. According to Nagasiri and Chitmongkolsuk's study, greater remaining tooth structure means greater longevity for the teeth.[5] A mini-invasive approach should be performed during all the steps of the treatment such as the access cavity preparation, root canal instrumentation and during the restoration procedures (post-space preparation, final cavity preparation, selection of the type of the restoration). It is also important to use conservative techniques during irrigation and canal obturation.[6]

(2) Bioeconomy of periodontal tissues

The 'ferrule effect' is crucial to optimize the biomechanical behavior of the restored tooth.[7] It is attained by preserving intact coronal and radicular tooth structure and maintaining cervical tissue A conservative approach in cavity preparation and restoration often means mini-invasive surgical crown lengthening, and sometimes, no periodontal surgery.

(3) Reinforcing of healthy residual dental tissues

Reinforcing effect of adhesive restorations have long been known.[8] Conservative bonded restorations are more and more preferred to traditional metal full crowns.[9] The best current approach for restoring endodontically treated teeth is to minimize tissue lostto create a ferrule effect especially in the cervical area, to use adhesive procedures to strengthen remaining tooth structure and optimize restoration stability and retention,

and also to use post and core materials with physical properties close to those of natural dentin.[10]

(4) Esthetic, ergonomic and economic advantages

Adhesive restorations offer an immediate appreciable aesthetic result due to its chromatic integration. The supragingival margins of the partial adhesive restorations result in healthy periodontal tissues and simplify oral hygiene techniques (brushing and flossing) and professional inspection. Indirect composite restoration which is an interim stage before placement of a full crown permits repair and replacement with the advantage of preserving the residual tissues for subsequent prosthetic treatment.[11]

Direct adhesive restorations

Direct restoration involves placement of a restorative material directly into the tooth. On one hand the bonded composite direct restoration is a conservative option that is possible to achieve, technically, by means of sectional matrix bands and separation rings. On the other hand, in line with the current international literature, this procedure is practicable only in the presence of small loss of healthy dental substance.

Indirect adhesive restorations
(onlay-overlay)

Partial indirect adhesive restorations should be preferred when possible as they are more conservative than prosthetic restorations. Adhesive overlays preserve coronal structure, avoid contamination of the root canal system, reinforce residual dental tissues, guarantee optimal form, function, aesthetics and offer ergonomic and economic undoubted clinical advantages.[1]

Onlay

An onlay indirect restoration could be performed in the loss of one marginal ridge and compromised two adjacent cusps when the other marginal ridge and cusps are healthy. (Figure 1) This restorative option is not frequently used in heavily compromised endodontically treated teeth. Typical indication includes molars damaged by one deep single decay with interproximal extension.

Overlay

In mesio-occlusal-distal cavities the risk of fracture is higher[12]; in endodontically treated posterior teeth when both marginal ridges are lost, a direct restoration is unacceptable and an overlay preparation with cusp coverage increases fracture resistance. (Figure 2) About 50% lower removal of tooth structure is required for overlay adhesive preparations when compared to the complete crown preparation. Adhesive techniques allow the clinician to preserve rather than remove dentine; the precision during the single phases of the procedure (build-up, cavity preparation, impression, luting, finishing and polishing) and the attention to many fine details thereby providing the basis of long-lasting, aesthetic restorations.

Amalgam restorations

Amalgam has been used as a direct restoration because of many clinical, practical and ergonomic advantages: optimal marginal seal, wear resistance and compression strength, good polishability, excellent costs-benefits ratio.[13] The amalgam posed several limitations: the intrinsic rigidity of the material, but most importantly the change in size, caused by the thermal expansion coefficient and expansion during the hardening phase which could increase the stress on dental tissues leading to micro-cracking. Silver amalgam was quickly replaced with the introduction of composite materials, not necessarily for toxicity problems, which have never been proven, or for its other limitations (corrosion, oxidation, gum tattoos, and galvanic currents), but for the advantages of the adhesive techniques that enable aesthetic, conservative and strengthening restorations on the residual healthy tissue.

Gold restorations

Gold was high-quality and noble alternative to the amalgam. Cast gold partial crowns (onlays, three-quarters, seven eights)

ensured conservative preparations, protection against bio-mechanical stress and optimal long-term reliability.[14] Despite their renowned durability, the use of gold restorations has decreased because of aesthetic limits. Today gold is still the material of choice for posterior teeth except when there is an esthetic concern. Second molars are good candidates for these types of restoration especially in case of limited interocclusal space or in bruxist patients.[15]

Full crowns

Long term prognosis of endodontically treated teeth gets improved once the cuspids are covered. The various adhesive techniques limited the use of full crowns in favor of partial procedures that guarantee the same protection with more conservative procedures. Today full crowns have fewer indications than in the past and, more specifically, are used for three clinical conditions; (1) for severe loss of coronal material from disease (decay or fractures) or iatrogenisis (preexisting full procedures with the involvement of dental tissues extending to the cervical third; (2) as a bridge component in a fixed prosthesis (when implants are contraindicated); (3) for perio-prosthetics.

Though aesthetic materials (ceramic zirconia-supported crowns, crowns in monolithic zirconia crowns, and lithium disilicate crowns) have been shown to offer optimal aesthetic and functional qualities over the short- and medium-term, we should not forget that only traditional metal-ceramic crowns have been scientifically shown to offer long-term reliability and thus represent the first choice, particularly in sectors and for patients with few aesthetic requirements. Regardless of the nature of the material used in the manufacturing of the crown, two aspects play a decisive role in the long-term success of the prosthetic tooth: the placement of an endodontic post and the detection of a cerclage or splint.

Endodontic posts

Endodontic posts should only be used in cases with severe loss of healthy coronal dental tissue caused by decay, fractures or iatrogenic damage that indicates the need for a full crown. Although in some cases endodontic posts are necessary, their use should be carefully assessed and avoided where possible for a series of reasons[16]: (1) Potential risk of stripping, particularly if inserted in thin and curved roots. (2) Increase the risk of root fracture. (3) Increased incidence of endodontic lesions (4) Risk of perforation. (5) Increases surgery times and costs (6) Adhesion to the root canal dentin remains a ''challenge'' for the clinician due to the negative impact of irrigants and disinfectants, the unfavorable cavitary configuration[7] and the technical/practical difficulties (removal of the gutta-percha, adhesive phases). The endodontic post is a rigid extension placed into the root canal for retaining materials in a coronal restoration through radicular anchoring. This is the principal reason for the use of a post. The second reason why posts are used is to strengthen the restoration complex/coronal dentin, which is subjected to tangential stress.[17] Other studies18have not confirmed the strengthening effect on the residual coronal portion and the post can thus be seen as an additional system for coronal- radicular retention, but not necessarily for strengthening.

Cast-gold posts were considered the gold standard for the restoration of endodontically treated teeth for many years. More recently all posts manufactured in rigid materials (gold, silver, titanium, zirconium) have been reassessed because, since they are very resistant with an elevated elastic modulus, they cause stress on dental tissues, increasing the risk of fracture. More recently posts with a more favorable elastic modulus have been preferred. Fiber posts provide an elastic modulus (20 GPa) very close to that of dentin (18 GPa) and enable a more uniform absorption and distribution of stress across the residual radicular structure. Carbon fiber posts [19], and more recently glass and quartz-fiber posts, have been used for over 20 years in the post-endodontic restoration of severely compromised components, with the goal of creating as uniform as possible a monoblock between

the post, reconstructive material, cement and tooth, with each component having physical characteristics (elastic modulus) as similar as possible to the others. Microflexions results due to biomechanical stress and consequential deformation under load of the tooth-restoration complex over time causing weakness in the adhesive bond and potential de-cementation. De-cementation, by preventing catastrophic consequences such as radicular fracture, can be considered a ''safety system'' for the dental component.

CASE REPORT

A 25 year old male reported to the department with a chief complaint of dislodged restoration in relation to lower left back tooth region. Patient gave a history of root canal treatment done on the same tooth 2years back and his medical history was non-contributory. Clinical examination revealed a moderate destruction of coronal tooth structure involving the mesiolingual aspect following the complete removal of temporary restoration. (Figure 3 &4) However the patient was asymptomatic and an IOPA radiograph in relation to[37] revealed a single canal with an incomplete root canal filling without any evidence of periapical lesion. (Figure 5) Therefore, endodontic retreatment (Re-RCT) was attempted.(Figure 6 & 7) The canals were then obturated using thermoplasticized obturation technique. (Figure 8) Crown lengthening was performed to provide adequate crown height in the mesiolingual aspect of the tooth. (Figure 9&10)

Various post endodontic treatment options were considered and proposed according to the patient's request for minimal treatment cost. Based on his demands, a conservative post endodontic management with a metal ceramic based overlay (PFM) was suggested and the treatment was executed following the patient's consent.

Clinical procedure for porcelain fused metal overlay

Following the opening of the root canal, the gutta percha was removed upto 2mm below the level of each orifice, followed by complete sealing of the coronal orifices and the pulp chamber (2mm thick) with glass ionomer (type II) restorative cement (GC Corporation, Tokyo, Japan) to obtain the resistance form.

Cuspal reduction of 1.5-2 mm in functional cusp and 1-1.5 mm on non functional cusp was done. The margins were leveled in the shape of a shoulder at high speed and under constant cooling system throughout the procedure ensuring a uniform thickness of 1.5mm with the remaining coronal tooth structure. The bur was oriented along the long axis of the tooth and maximum efforts were attempted to maintain an occlusal divergence of 70 to 100 to ensure a continuous flow of the prepared coronal pulp chamber and the access cavity. (Figure 11)The shouldered walls and margins were then smoothened with a finishing bur.

Impression was made with polyvinyl siloxane material using a putty wash technique and was sent to the laboratory for further processing. Temporization was done to maintain the dimension of the prepared tooth in the inter appointment period. In the subsequent appointment, following the evaluation of final fit, the fabricated PFM based overlay on 37 was luted with Type 1 GIC (GC Corporation, Tokyo, Japan) and cemented under adequate isolation control.(Figure 12 to 17) .

Conclusion

The long-term success of the restoration of endodontically treated teeth is influenced by operative choices selected by the clinician in function of the individual clinical case: direct or indirect restorations, overlays or full crown, need for post placement, selection of materials and the principles used in the design preparation. The treatment planning depends on remaining coronal tooth structure, tooth position in the arch, occlusion, missing teeth, parafunctions and rehabilitation planning.

• Amalgam restoration • Composite resin restoration	• Direct restoration
• Composite resin onlay/overlay • Composite resin onlay/overlay (CAD-CAM) • Ceramic onlay/overlay - lithium disilicate (pressed) • Ceramic onlay/overlay - lithium disilicate (CAD-CAM) • Gold overlay	• Inlay
• Metal-ceramic crown • Zirconia-ceramic crown • Monolithic zirconia crown • Ceramic crown - lithium disilicate (pressed and layered) • Ceramic crown - lithium disilicate (pressed) • Ceramic crown - lithium disilicate (cad-cam) • Gold crown	• Full crown

Table 1: Therapeutic options for the restoration of single posterior treated teeth 1

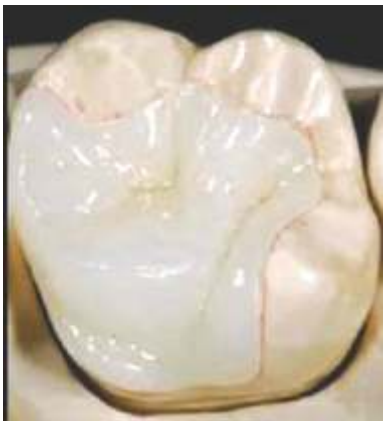

Figure 1. Onlay

Figure 2. Overlay

Figure 3. Pre-operative view of 37

Figure 4. Moderate amount of tooth destruction seen after the removal of the temporary filling.

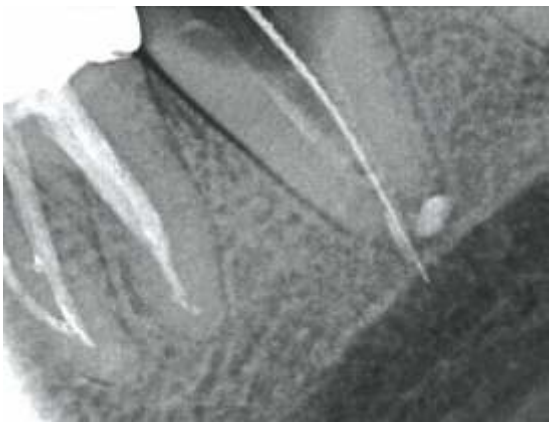

Figure 5. Working length determination showing the presence of a single canal.

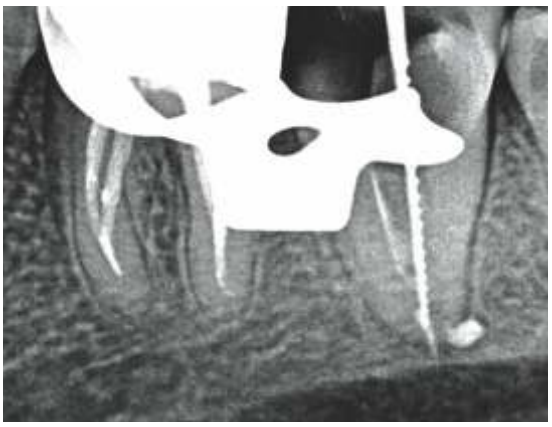

Figure 6. Canal with the master file

Figure 7
Canal with the master gutta percha cone

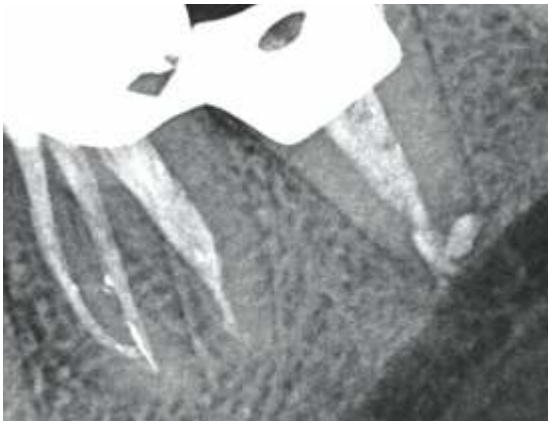

Figure 8. Canals obturated with thermoplasticized obturation technique

Figure 9. Crown lengthening done

Figure 10. Sutures placed

Figure 11- Tooth preparation done

Figure 12- Proximal view of the overlay

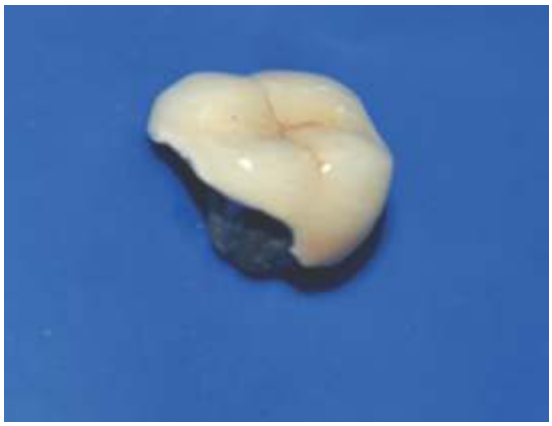

Figure 13- Buccal view of the overlay

Figure 14- Intanglio surface of the overlay

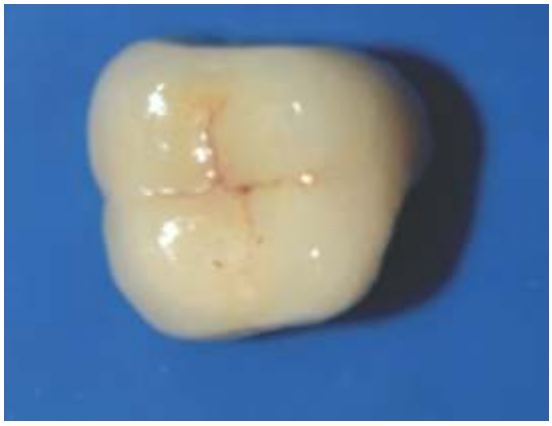

Figure 15- Occlusal view of the overlay

Figure 16- Cementation of the overlay done

Figure 17- Post operative radiograph

REFERENCES

1. Polesel A. Restoration of the endodontically treated posterior tooth. GiornaleItaliano di Endodonzia. 2014 Jun 1;28(1):2-16.
2. Ray HA, Trope M. Periapical status of endodontically treated teeth in relation to the technical quality of the root filling and the coronal restoration. Int Endod J 1995;28:12-8.
3. Mannocci F, Bhuva B, Stern S. Restoring teeth following root canal re-treatment. Endod Topics 2011;19:125-52.
4. Heling I, Gorfil C, Slutzky H, Kopolovic K, Zalkind M, Slutzky Goldberg I. Endodontic failure caused by inadequate restorative procedures: review and treatment recommendations. J Prosthet Dent 2002;87:674-8.
5. Nagasiri R, Chitmongkolsuk S. Long-term survival of endodontically treated molars without crown coverage: a retrospective cohort study. J Prosthet Dent 2005;93:164-70.
6. Tang W, Younong W, Smales R. Identifying and reducing risks for potential fractures in endodontically treated teeth. J Endod2010;4:609-10.
7. McLean A. Predictably restoring endodontically treated teeth. J Canadian Dental Assoc 1998;64:782-7.
8. Sheth JJ, Fuller JL, Jensen ME. Cuspal deformation and fracture resistance of teeth with dentin adhesives and composites. J Prostheth Dent 1988;60:56-569.
9. Magne P. No post, no crown: biomimetic restorative dentistry; 2008.
10. Dietschi D, Duc O, Krejci I, Sadan A. Biomechanical considerations for the restoration of endodontically treated teeth: a systematic review of the literature: Part 1. Composition and micro- and macrostructure alterations. Quintessence Int 2007; 38:733-43.
11. Cavalli G. Cap 12: Il restauro del dente trattatoendodontica- mente. Odontoiatria Conservativa procedure di trattamento e prospettive future. Milano: Elsevier Masson; 2009.
12. Hansen EK, Asmussen E, Christiansen NC. In vivo fractures of endodontically treated posterior teeth restored with amalgam. Endod Dental Traumatol1990;6:49-55.
13. Anderlini G. Moderniorientamenti per la restaurazionedentale. Bologna: Edizioni Martina; 1995.
14. Mangani F. Coroneparziali in oro per ilrestaurodeglielementi posteriori trattatiendodonticamente. Giornale Italiano Endo 1988;2:37-45.
15. Mannocci F, Cowie J. Restoration of endodontically treated teeth. Br Dental J 2014;6:341-6.
16. Polesel A. Il restauroconservativo del dente singolo posterior trattato endodonticamente. GiornaleItaliano Endo 2011;25: 3-21.
17. Schwartz R, Robbins JW. Post placement and restoration of endodontically treated teeth: a literature review. J Endod2004; 30:289-301.
18. Fokkinga. et al. Ex vivo fracture resistance of direct resin composite complete crowns with and without posts on maxillary premolars. Int Endod J 2005;38:230-7.
19. Duret B, Reynaud M, Duret F. Un nouveau concept de reconstitution coronradiculare: le Composipost. Le Chir Dent Fr 1990;54:131-41.