Radicular Cyst - a review

Afna Nasser*, Giju George Baby,Vineet Daniel Alex***, Hima John****, Anish N*****

*Final BDS Student, Annoor Dental College & Hospital
**Principal & HOD, Oral Medicine & Radiology, Annoor Dental College & Hospital
***Reader, Oral Medicine & Radiology, Annoor Dental College & Hospital
****Senior Lecturer, Oral Medicine & Radiology, Annoor Dental College & Hospital
*****Senior Lecturer, Oral Medicine & Radiology, Annoor Dental College & Hospital

Corresponding Author
Dr Anish N, Senior Lecturer, Oral Medicine & Radiology,
Annoor Dental College & Hospital, Muvattupuzha – 686673
Mob: 9496978687, email id: anishnsh2727@hotmail.com

Abstract

OBJECTIVES:

Radicular Cyst(RC), also termed as Periapical Cyst, is reported as the most common odontogenic cyst which involves the apex of a carious tooth. It may also be seen associated with lateral aspects of the roots in relation lateral accessory root canals. RC is considered as a true cyst, as it consists of a fluid filled pathological cavity lined by epithelium, originating from epithelial residues in periodontal ligament. Both surgical and non-surgical methods are used for its management. Quite often, the RC remaining after the removal of the offending tooth is denoted as Residual Cyst.

Keywords:

Radicular Cyst, Periapical cyst, Odontogenic, Periodontal Ligament, Enucleation

Introduction

As per definition, Cyst is a pathologic cavity lined by epithelium, containing fluid or semi-solid material[1].Cysts originating from epithelium associated with the development of dental apparatus are termed as Odontogenic Cysts (OC).[1] OC's may originate from tooth germ, epithelial cell rests of malassez, reduced enamel epithelium, remnants of dental lamina or from the basal layer of oral epithelium.[1] Radicular Cyst, considered as the most common odontogenic cyst, originates from the apex of erupted tooth as a sequel of periapical granuloma occurring as a result of bacterial infection and necrosis of dental pulp, following carious tooth involvement.1The epithelium from the epithelial cell rests of malassez in the periodontal ligament, of a pre-existing periapical granuloma, proliferate as a result of inflammatory stimulus resulting in the formation of RC.[1]

Epidemiology

Radicular cysts are the most common of all jaw cystscomprising of 52 -68% of all cysts.[2] Considered to be rare in primary dentition, it comprises of 0.5 - 3.3% in both primary and permanent dentition.[3] Along with traumatic injuries to primary teeth, dental caries has been reported to be the most frequent etiological factor.[3] Among all periapical osteolytic lesions associated with endodontically treated teeth, the prevalence of RC's is only 15%, of which 9% are true cysts and 6% are pocket cysts.[4] With a slight male predilection, they more commonly occurs between 3rd to 5th decades of life, mostly in anterior maxillary region and mandibular premolar region.[1,4]

Pathogenesis

It is still not completely understood that how RC is formed resulting from endododontic infection. Among the several theories proposed, the 'nutritional theory', 'abscess theory' and 'merging of epithelial bands theory' are the most popular, but still lacking a strong base, considering the aspect of epithelial cell biology.[5] According to 'nutritional deficiency' theory, a ball mass is formed from over proliferated epithelial cells and the cells in the centre will be deprived of nutrition.[5] The outer cell layer depends on the nutrition obtained from the basement membrane and they will always move toward nutritional source.[5] Due to this, the more central epithelial cells move away from their nutritional supply and undergo necrosis. A cystic cavity is formed in the centre of the cell mass resulting in liquefaction necrosis.[5] According to abscess theory, whenever an abscess cavity is formed within the connective tissue, epithelial cells at the site proliferate and line the pre-existing cavity due to their inherent tendency to cover exposed connective tissue surfaces.[5] Nair et al;2008, investigated about this phenomenon and proposed 3 phases of cyst formation;

1) dormant epithelial cell rests proliferate

2) epithelium-lined cavity established and

3) the cyst grows.[5,3]

According to the 'merging of epithelial strands theory'; as the epithelial strands continue to grow, they merge to form a three-dimensional ball mass. The connective tissue trapped inside the ball mass undergoes degeneration, resulting in the formation of a cyst.[5]

Clinical Features

Being usually asymptomatic, RC's are unnoticed until they get detected during routine radiographic examination.[1] Acute exacerbation of cystic lesion may occur on long standing cases and develop signs and symptoms including swelling, tooth mobility and displacement of unerupted teeth.[1]Involved tooth will be non-vital and may also show discolouration.[1] The associated swelling may be buccally or palatally in the maxilla, and in the mandible it will be usually in the buccal aspect.[1] The swelling initially may be bony hard, but along with the increase in the size of the cyst, the bony outer covering may become thin and exhibit springiness or egg shell crackling, despite the sub periosteal bone deposition.[1,6] When the cyst erodes the bone completely, it may also become fluctuant.[1]

Investigations

On Aspiration of cystic content, Radicular Cyst may show gold or straw coloured fluid due to the presence of cholesterol crystals.[7] Total protein content of RC may range between 5 - 11g/100 ml.[7] By these features, RC's can be differentiated from Odontogenic Keratocyst (OKC) which shows dirty white cheesy material and Dentigerous Cyst(DC) showing thin watery yellow straw coloured fluid.[6,7] The total protein content of OKC will be <5g/100 ml which is lower than that in serum, and that of DC is usually 4 - 8 g/100 ml.[7]

Radiographic Features

Usually RC's presents as a round or pear

shaped radiolucent region, with a thin cortical outline in the periapical region of a tooth with an infected necrotic pulp on conventional radiography and cone beam computed tomography.[1,4] RC's usually presents as unilocular radiolucency more than 2cm, but unusual cases of RC's presenting as bilocular radiolucencies has also has been reported (Figure 1,2).[1,3] RC's arising from deciduous teeth, mostly affects mandibular teeth and also may mimic dentigerous cyst, especially when multilocularity is present.[1]

Histological Features

In active infection, thick and irregular epithelial lining associated with infiltrate of inflammatory cells may be detected.[4] In case of inactive infection, the epithelial lining will be thin and inactive and will be having minimal amount of inflammatory cells.[4] RC's will be lined by stratified squamous non- keratinized epithelium, which may be discontinuous with a thickness ranging from 1 - 50 cell layers.[1] Initially, the lining epithelium may show arcading with inflammatory infiltrates and as the cyst enlarge, they become fairly regular and may resemble simple stratified squamous epithelium.[1] Keratin formation in the cyst wall may be detected in about 2% cases.[1] Cholesterol crystals may be detected within the cystic lumen.[4] Histologically, two variants of RC's may be detected, namely true cyst or pocket(bay) cysts. True cyst will completely lined by epithelium and in pocket cysts, the cystic lumen opens into apical canal of the involved tooth root.[4]

Treatment

Treatment protocol depends on various factors namely extension, relation with other structures, evolution, clinical features, origin, systemic condition and co-operation of the patient.[1] Treatment aims to eradicate microbes from the root canal and prevent reinfection, for which the options include conventional Root Canal Treatment, enucleation, marsupialization, decompression or a combination approach.[1,2] Even though endodontic approach possess a high success rate, it may fail if it did not attain a satisfactory standard for the control and elimination of infection.[2] Rarely factors located within inflamed periapical tissue may interfere with healing during the post treatment period.[4] RCT associated with apicectomy also may tried alternatively.[2] Lesions not subsiding by the above said measures has to be managed by extraction of the involved non-vital tooth and curettage of the epithelium in the periapical region.[2]

Fig 1. Maxillary Occlusal Radiograph showing Radicular Cyst

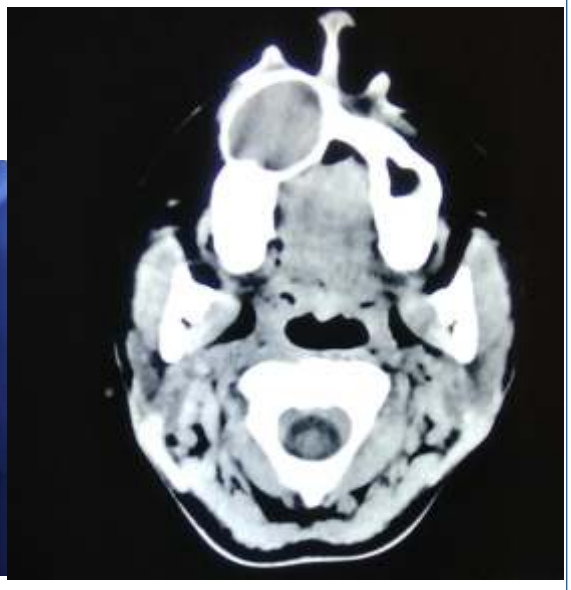

Fig 2. CT image showing Radicular Cyst

Conclusion

Radicular Cyst, inflammatory in origin, occurring in the periapical area of a tooth with necrotic pulp, is a common condition, usually go unnoticed because of its asymptomatic nature. Radiographically detected during routine radiographic examination as a round osteolytic lesion with a thin cortical outline, is almost impossible to diagnose clinically. Tissue destruction and facial deformity may result in untreated cases. Even if authors propose endodontic treatment followed by surgical enucleation, surgical and other nonsurgical management techniques, considering the location, size, nature and relation of the cyst to adjacent structures, specific treatment for the same is still debatable.

References:

1. Harshitha KR et al. Radicular Cyst: A case report. International Journal of Applied Sciences 2015;1(4):20-22
2. Latoo S et al. Radicular Cyst. JK Science 2009;11(4): 187-89
3. Narsapur SA et al. Radicular cyst associated with deciduous molar: A report of a case with an unusual radiographic presentation. Indian Journal of Dental Research 2012; 23(4):550 -53
4. Lin LM et al. Radicular Cysts Review. JSM Dent Surg 2017;2(2): 1-3
5. Huang GTJ. Apical Cyst Theory: a missing link. Dent Hypothesis 2010;1(2):76-84
6. Mantu VK, Mitra R. Radicular Cyst, a Case Report and its Histopathological Analysis. International Journal of Advanced Health Sciences 2015; 2(5): 9 - 12
7. Prakash R et al. Comparison of components of odontogenic cysts fluid: A review. Journal of Medicine, Radiology, Pathology and Surgery 2016;2(2):15-17
8. SM Balaji. Cysts of the Oral Cavity. In: SM Balaji eds. Textbook of Oral and Maxillofacial Surgery, 1st ed. India: Elsevier; 2008. pp 340 - 362.

A PARULIS / GUM BOIL

represents a focus of pus in the gingiva. It is derived from an acute infection either at the base of an occluded periodontal pocket or at the apex of a non-vital tooth. The lesion appears as a yellow-white gingival tumescence with an associated erythema. A pain is typical, but once the pus escapes to the surface, symptoms is temporarily relieved. Treatment of the underlying condition {periodontal pocket or non-vital tooth} is required to achieve resolution of the gingival abscess.

Reference:
Regezi J.A, Sciubba J.A, Jordan R.C.K;Oral Pathology-Clinical Pathologic Correlations; St. Louis,Missouri;Saunders 2003;Chapter3;107-18.

Abin Jose Cyriac
Final Year BDS Part I

Clinical Picture

Radiograph